

careum Weiterbildung

## Operationen in der Urologie

Transurethrale Standardeingriffe

Dr. C. Wetterauer | April 2019 | 03.04.2019

---

---

---

---

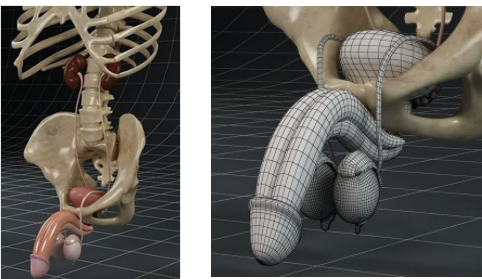
---

---

---

---

### Anatomie Basics



careum Weiterbildung, Aarau <https://img-new.cgtrader.com>, <https://www.cgtrader.com> 1

---

---

---

---

---

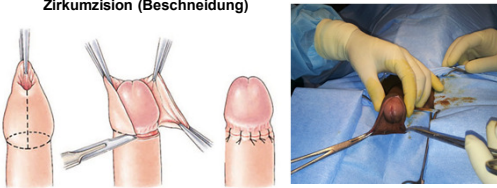
---

---

---

### Äussere Eingriff - Wundversorgung

#### Zirkumzision (Beschneidung)



careum Weiterbildung, Aarau 2

---

---

---

---

---

---


---

---

### Äussere Eingriff - Wundversorgung

**Hydrozelen- /Spermatozelenresektion**

Gelegentlich mit Drainage



Abdominal cavity, Epididymis, Testicle, Scrotum

<http://www.urologygroupvirginia.com/assets/NewFolder/3169991527001.jpg>  
[https://io.quizlet.com/item/2/1/uk0gqz3f/1/uc07g\\_m.jpg](https://io.quizlet.com/item/2/1/uk0gqz3f/1/uc07g_m.jpg)  
<http://www.ovariancystmiracle.com/Ovarian-Cyst-Video.php?top=5ewia25>

Carum Weiterbildung, Aarau 3

---

---

---

---

---

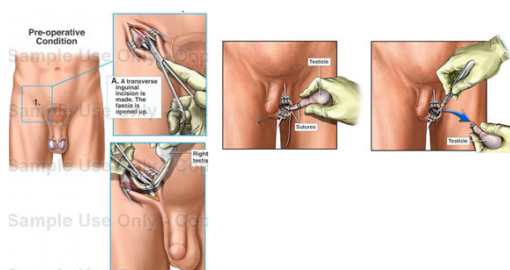
---

---

---

### Äussere Eingriff - Wundversorgung

**Ablatio testis / (radikale) Orchiektomie (inguinal oder skrotal)**



Pre-operative Condition

A transverse inguinal incision is made. The testis is opened up.

Testis, Epididymis, Sutures, Testis

Carum Weiterbildung, Aarau 4

---

---

---

---

---

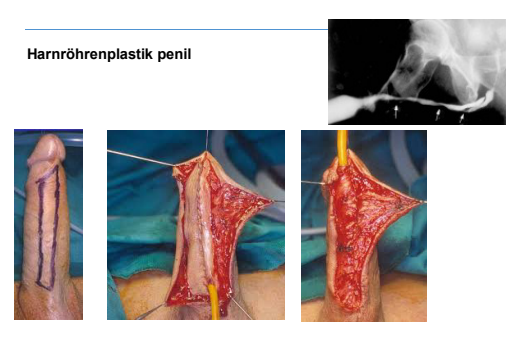
---

---

---

### Äussere Eingriff - Wundversorgung

**Harnröhrenplastik penil**



Carum Weiterbildung, Aarau [http://www.urethralcenter.it/pdf/lecture\\_barbagli/hong-kong1.pdf](http://www.urethralcenter.it/pdf/lecture_barbagli/hong-kong1.pdf) 5

---

---

---

---

---

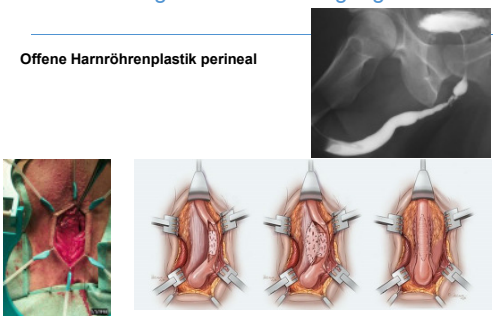
---

---

---

### Äussere Eingriff - Wundversorgung

**Offene Harnröhrenplastik perineal**



Carum Weiterbildung, Aarau

[http://www.urethralcenter.it/foto\\_sinominate/estologia/66.jpg](http://www.urethralcenter.it/foto_sinominate/estologia/66.jpg)  
<https://www.centerforreconstructiveurology.org>

6

---

---

---

---

---

---

---

---

### Äussere Eingriff - Wundversorgung

**Penisbegradigung nach Nesbit**



Carum Weiterbildung, Aarau

<http://au.amegroups.com/article/view/1707/2426/4975>

7

---

---

---

---

---

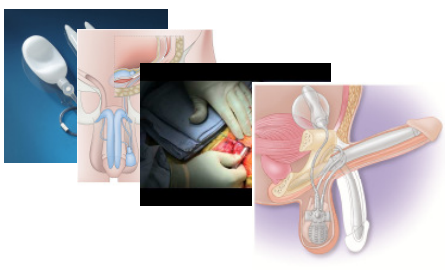
---

---

---

### Äussere Eingriff - Wundversorgung

**Penisprothese (AMS 700)**



Carum Weiterbildung, Aarau

<https://www.urologicalcare.com>; <http://www.garber-online.com>  
<http://i.yimg.com/vi/NqeOheikVYU.jpg>; <http://palgrave.nature.com>

8

---

---

---

---

---

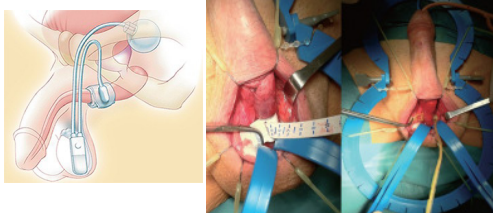
---

---

---

### Äussere Eingriff - Wundversorgung

#### Sphinkterprothese (AMS 800)



Carum Weiterbildung, Aarau <http://img.medscapestatic.com>, <http://www.ajandrology.com>, <http://www.bostonscientific.com> 9

---

---

---

---

---

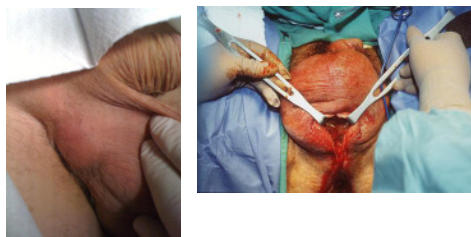
---

---

---

### Äussere Eingriff - Wundversorgung

#### Skrotalabszess



Carum Weiterbildung, Aarau <http://emedicine.medscape.com> 10

---

---

---

---

---

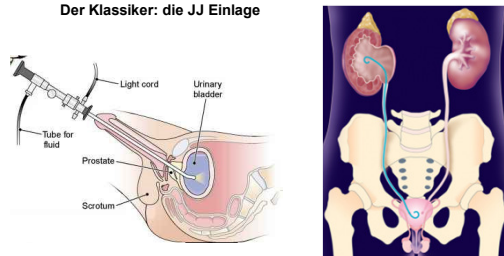
---

---

---

### Endourologie

#### Der Klassiker: die JJ Einlage



<http://www.urology.textbook.com/ureteroscopy.html>  
<http://www.lowerurology.com/wp-content/uploads/2012/11/UJ1.png>  
[http://www.78stepshealth.us/medical-terminology/images/2431\\_182\\_194-cystoscopy.jpg](http://www.78stepshealth.us/medical-terminology/images/2431_182_194-cystoscopy.jpg) 11

Carum Weiterbildung, Aarau

---

---

---

---

---

---


---


---

**Endourologie**

---

**URS**

Starr / semirigide 

Flexibel 

Careum Weiterbildung, Aarau <http://www.uro-luebigen.de>, <http://www.sankt-katharinen-rlm.de> 12

---

---

---

---

---

---

---

---

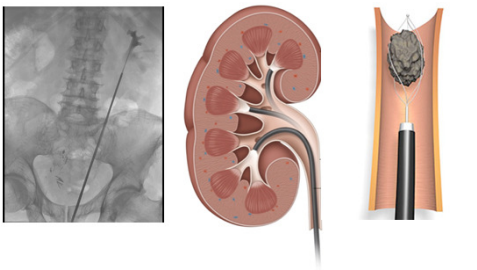
---

---

**Endourologie**

---

**URS**



Careum Weiterbildung, Aarau <https://www.healthcare.siemens.com>, <http://www.sankt-katharinen-rlm.de> 13

---

---

---

---

---

---

---

---

---

---

**Endourologie**

---

**TUR-Blase bei Blasen-tumor**

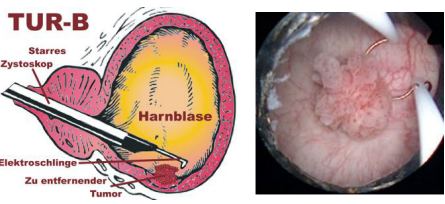
**TUR-B**

Starrs Zystoskop

Harnblase

Elektroschlinge

Zu entfernender Tumor



Careum Weiterbildung, Aarau <http://www.urologielehrbuch.de/01/TURB1.jpg>, <http://www.krebszeilung.de/wp-content/uploads/2012/05/tur-b-zeichnung.jpg> 14

---

---

---

---

---

---

---

---

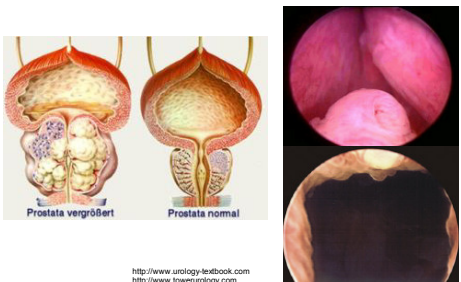
---

---

Endourologie

---

**TUR-Prostata bzw. XPS Laservaporisation**



Prostata vergrößert      Prostata normal

Carum Weiterbildung, Aarau  
http://www.urology-textbook.com  
http://www.7stepshealth.us

15

---

---

---

---

---

---

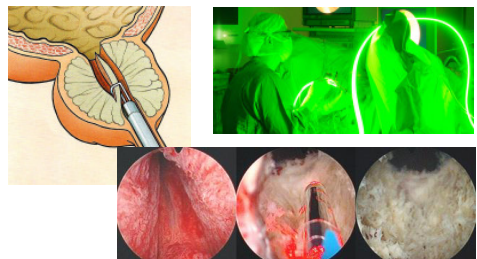
---

---

Endourologie

---

**TUR-Prostata bzw. XPS Laservaporisation**



Carum Weiterbildung, Aarau  
http://die-prostata.com, https://www.unispital-basel.ch  
http://www.urologielehrbuch.de

16

---

---

---

---

---

---

---

---

Der Spül-Katheter, die Blasen-spülung – warum? Und wann?



Spülung muss laufen! -> klarer Urin

https://upload.wikimedia.org/wikipedia/commons/f/f8/Basen-katheter.PNG  
http://www.farmed.de/magazin/product\_image/afb\_01/mage/bsp/katheter\_01\_482\_1.jpg

17

---

---

---

---

---

---

---

---

**Abdominaleingriffe**

---

**(Tumor-) Nephrektomie offen oder endoskopisch**

Copyright ©2009 by The McGraw-Hill Companies, Inc. All rights reserved.

Carum Weiterbildung, Aarau <http://ueu.co/wp-content/uploads/2014/09/loadBinaryCAXCF8R2.jpg>  
<https://s-media-cache-ak0.pinimg.com/736x/97/c1/e5/97c1e597c1e57e946bb867b6113e65a43e6c4.jpg>

---

---

---

---

---

---

---

---

---

---

---

---

**Abdominaleingriffe**

---

**(Tumor-) Nephrektomie offen oder endoskopisch**

Copyright ©2009 by The McGraw-Hill Companies, Inc. All rights reserved.

Carum Weiterbildung, Aarau <http://keyholeurology.co.uk/images/portplacements.jpg>, <http://img.medscape.com>  
<http://www.pkdiel.com/pdf/Laparoscopic%20nephrectomy.pdf>

---

---

---

---

---

---

---

---

---

---

---

---

**Abdominaleingriffe**

---

**(Tumor-) Nephrektomie**

Easyflow Drainage  
 Unterbauch ausgeleitet  
 Liegt intraperitoneal (hohe Sekretion)  
 Fixieren!

Copyright ©2009 by The McGraw-Hill Companies, Inc. All rights reserved.

Carum Weiterbildung, Aarau

---

---

---

---

---

---

---

---

---

---

---

---

**Abdominaleingriffe**

---

**Zystektomie und Harnableitung**

Labels in diagram: Kidney, Ureter, Section of ileum used to form conduit, Both ureters incised, Bladder removed, Urethra incised, Ureters attached to ileal conduit, Stoma - opening for catheter, Midline scar.

Source: Careum Weiterbildung, Aarau. [http://static1.squarespace.com/http://www.kegel8.co.uk/media/wysiwyg/normal\\_bladder\\_and\\_neobladder.jpg](http://static1.squarespace.com/http://www.kegel8.co.uk/media/wysiwyg/normal_bladder_and_neobladder.jpg)

---

---

---

---

---

---

---

---

---

---

---

---

**Abdominaleingriffe**

---

**Zystektomie und Harnableitung**

Labels: Neoblase, Ileumconduit, Kidney, Ureter, Section of ileum used to form conduit, Both ureters incised, Urethra incised, Ureters attached to ileal conduit, Stoma - opening for catheter, Midline scar.

Additional text: 2 Ureteren-katheter, 1-2 Drainagen Im Unterbauch

Source: Careum Weiterbildung, Aarau. [http://static1.squarespace.com/http://www.kegel8.co.uk/media/wysiwyg/normal\\_bladder\\_and\\_neobladder.jpg](http://static1.squarespace.com/http://www.kegel8.co.uk/media/wysiwyg/normal_bladder_and_neobladder.jpg)

---

---

---

---

---

---

---

---

---

---

---

---

**Abdominaleingriffe**

---

**Radikale Prostatektomie**

Labels: Zustand vor der Operation, Zustand nach der Operation, Prostata, Uterus, Blase, Harnleiter, Harnröhre, Harnblase, Harnleiter, Harnröhre, Harnblase.

Source: Careum Weiterbildung, Aarau. <http://gsurology.com.au/wp-content/uploads/2015/09/Open-Radical-Prostatectomy.jpg>

---

---

---

---

---

---

---

---

---

---

---

---



### Abdominaleingriffe

---

#### Radikale Prostatektomie

<http://www.davincizentrum-hannover.de>, 
 <http://www.urologygroupvirginia.com>, 
 <http://www.montereybayurology.com>, 
 <http://1.bp.blogspot.com>, 
 <http://www.wellobbildung.de>

---

---

---

---

---

---

---

---

---

---

### Wichtig für die tägliche Routine

---

- Operationen am Äusseren Genitale Wuko, kühlen, hochlagern
- Spülkatheter Muss immer laufen!
- Ureterenkatheter UK Anspülen n. Anordnung
- Blasen tamponade Ausräumung mit Arzt
- DK nach transurethralem Eingriff 2-3d
- DK nach Prostatektomie 5-10 Tage
- DK nach Neoblase 14 Tage

Careum Weiterbildung, Aarau
25

---

---

---

---

---

---

---

---

---

---

### FRAGEN??

---

Careum Weiterbildung, Aarau
26

---

---

---

---

---

---

---

---

---

---